

# Aging collagen in the human reticular dermis

proderm GmbH, G. Springmann, G. Kourbaj, H. Gilicki, M. Seise, S. Bielfeldt

## Background

With a share of 90%, collagen is the most abundant protein in the dermis. It forms a fine network of fibers and is largely responsible for the skin's resistance and elasticity. With increasing age, collagen degrades and fibers become cross-linked. Skin elasticity decreases and wrinkles form. A major cause of collagen loss and degradation is sun exposure. UV-A rays penetrate into the dermis and generate free radicals. The skin reacts to this, for example, with the formation of metalloproteinases, enzymes that cut collagen fibers, and the collagen degrades.

Imaging of the collagen network by invasive methods using punch biopsies and histological staining has long been established. However, in cosmetic research, noninvasive methods should be used whenever possible. A number of imaging techniques that can be applied directly to living skin are available. Line Confocal Optical Coherence Tomography (LC-OCT) is a newer imaging technique with high resolution. The aim of this work was to assess the age-related collagen degradation as visualized by LC-OCT images of reticular collagen acquired in subjects of different ages using LC-OCT.

## Method

In 43 male and female subjects aged 7-70 years with fair skin and no signs of pronounced photoaging, images of reticular collagen were obtained with LC-OCT. Images were taken on the inner, sunlight-protected forearm and on the sun-exposed dorsal forearm respectively. Collagen content was evaluated by image analysis. Main criterion was the optical attenuation as a measure for the density and reflectiveness of the collagen structure.

## Conclusion

The LC-OCT method as a non-invasive in vivo method was found to be well suited to visualize signs of aging of collagen in the reticular dermis. The results observed complement the literature documented collagen imaging and measurement. Advantageous is the fast image acquisition and the spatial resolution of about 1  $\mu\text{m}$ , which is excellent for confocal systems. However, the collagen of the deeper reticular dermis cannot be evaluated with this method, since the images clearly lose sharpness and contrast from a depth of about 200  $\mu\text{m}$  on. For an evaluation of the collagen in the uppermost reticular dermis, the method is well suited.

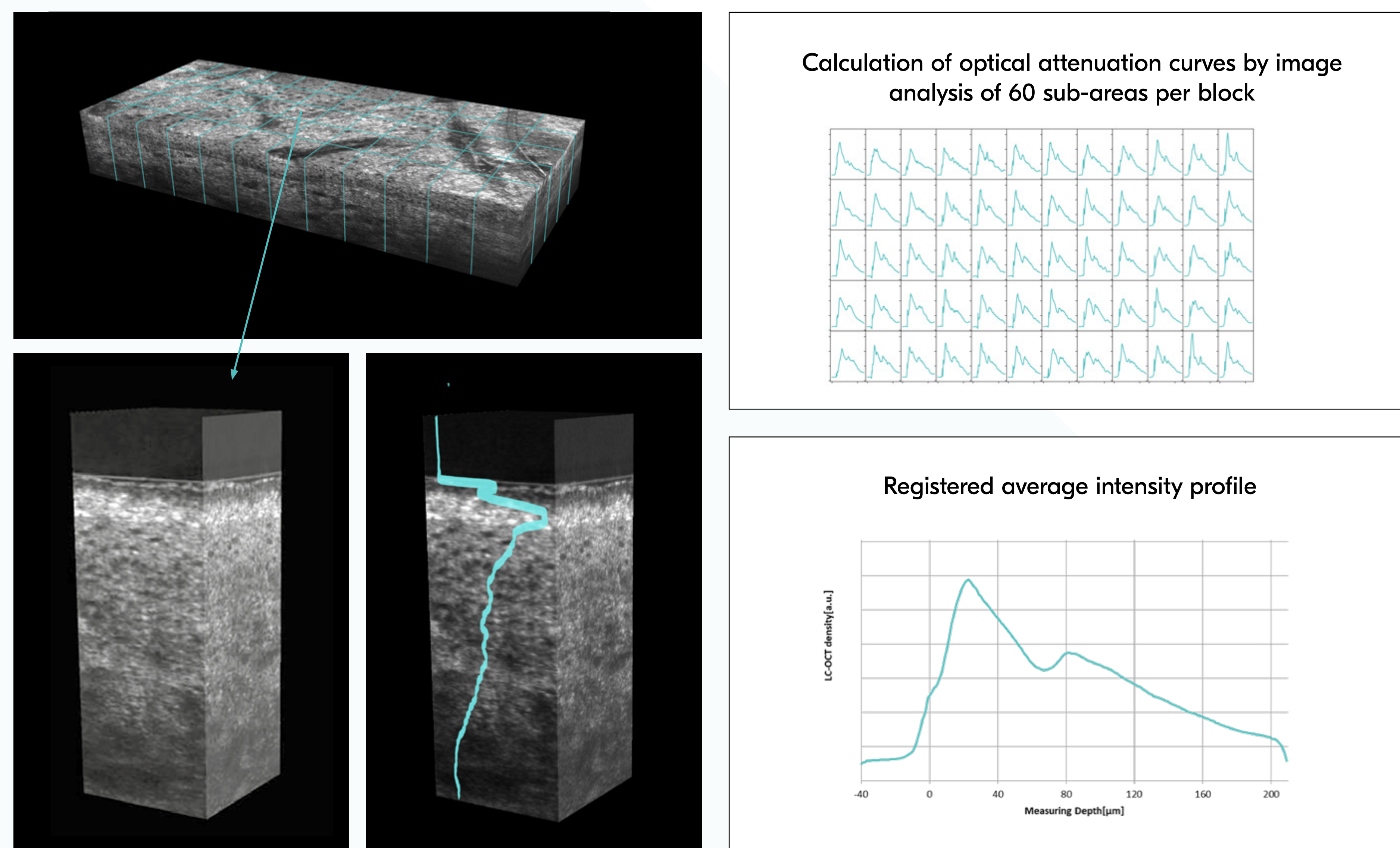


Figure 1 Visualization of the dermal optical attenuation. This is the negative slope of the attenuation curve of tissue reflectivity, closely below the dermo-epidermal junction (red part of the curve in Figure 3).

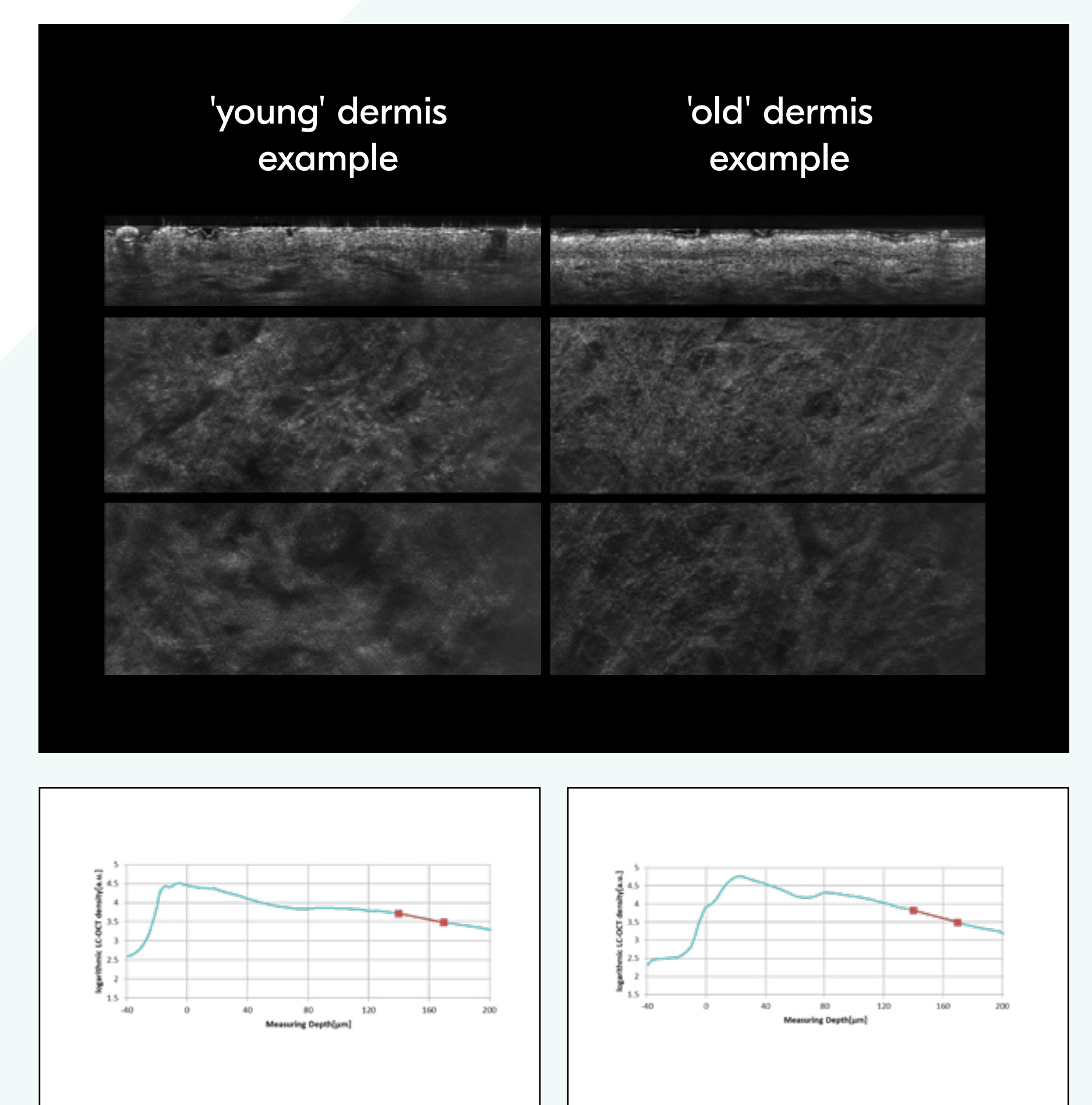


Figure 3 Visualization of optical attenuation in young and old dermis

## Results

Visual assessment of LC-OCT images revealed an age-related decrease in density and reflectiveness of the collagen. Aged collagen was more fibrous and increasingly embedded in dark non reflective structures. Intra-individual differences between dorsal and volar collagen pattern gradually became larger with increasing age, as the dorsal collagen change started earlier at age and developed quicker.

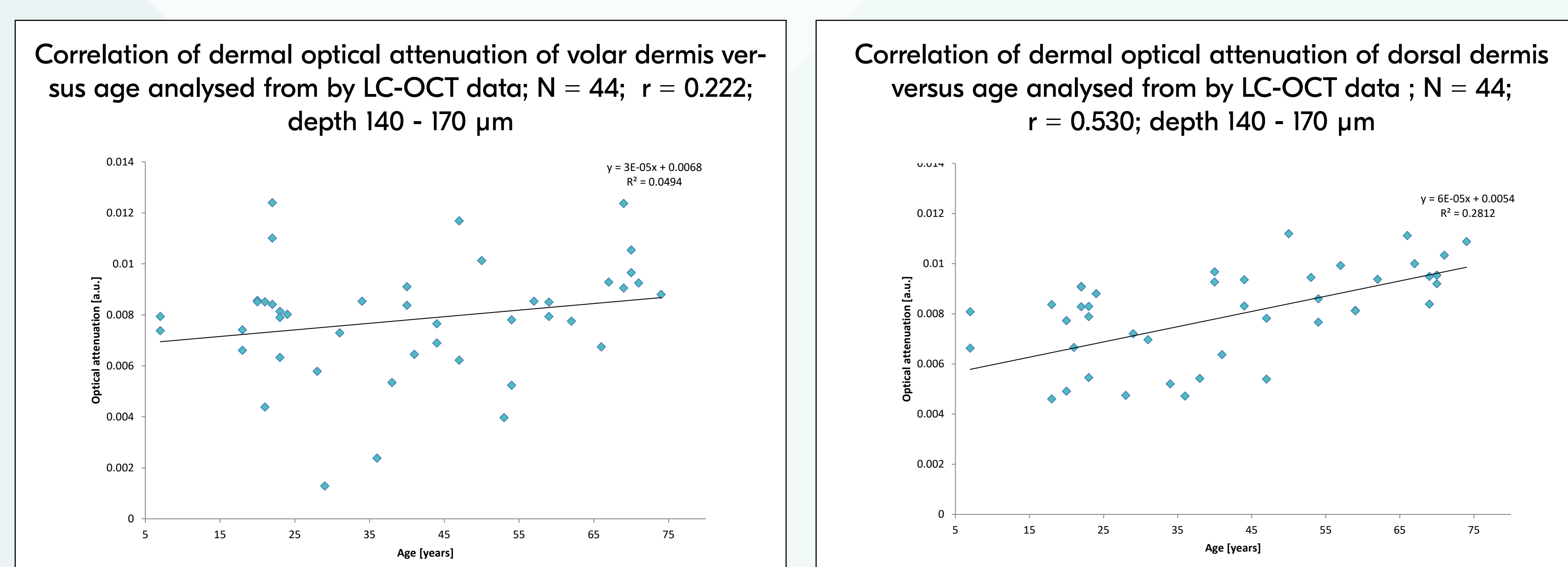


Figure 2 Correlation of dermal optical attenuation of dorsal dermis at a depth of 140-170  $\mu\text{m}$  vs age for all valid subjects as measured by LC-OCT (n = 44)